

**CASE REPORT****Excision of irritational fibroma of tongue with laser: a case report**Mohammad Uvais Khan<sup>1</sup>, Anudeepika Kashyap<sup>1</sup>, Karishma Agarwal<sup>1</sup>, Jharna Bharali<sup>1</sup>**ABSTRACT**

Reactive hyperplastic outgrowths are seen in the oral cavity due to many factors like chronic irritation by plaque, calculus, overhanging margins, trauma and dental appliances. Irritation fibroma represents a reactive focal fibrous hyperplasia due to trauma or local irritation.

The purpose of this article is to present a case report of the surgical removal of an irritation fibroma by diode laser.

**Keywords:** Irritation fibroma, diode laser

*1. Post-graduate Student*

*Department of Periodontics*

**\*Correspondence Address:**

*Dr. Mohammad Uvais Khan*

*Post-graduate student,*

*Department of Periodontics,*

*Kothiwal Dental College and Research Centre,  
Moradabad, 244001.*

*Email: mohammaduvaishkhan@gmail.com*

it must be biopsied and/or further evaluation is necessary for an appropriate diagnosis.<sup>2</sup>

**Working classification of common superficial tongue lesions**

Injury.

- Physical, chemical and thermal

Infections

- Bacterial: Tuberculosis and Scarlet fever
- Viral: Human immunodeficiency virus (HIV) and hairy leukoplakia
- Fungal: Candidiasis

Developmental disturbances

- Macroglossia
- Geographic tongue
- Fissured tongue
- Median rhomboid glossitis
- Hairy tongue

Nutritional deficiency

- Iron deficiency anemia
- Pernicious anemia
- Vitamin deficiency

Premalignant

- Leukoplakia
- Oral submucous fibrosis

**Introduction**

Local reactive focal overgrowths are frequently found in the oral cavities.<sup>1</sup> Since the earliest days of medicine, the tongue has been considered a good reflection of systemic diseases. Assessment of the tongue has historically been an important part of a clinical medical examination as many pathological lesions are seen exclusively on the tongue. Lesions occurring on the tongue are vast and range from developmental disorders to infections to idiopathic lesions to malignancies; some lesions may be clues to the underlying systemic illness. A basic and thorough knowledge of the commonly occurring lesions on the tongue may enlighten the general practitioner in regards to the diagnosis and thereby help in the most effective management of the patients. Most lesions occurring on tongue heal fast owing to the rich blood supply and if a lesion fails to heal within 10-14 days

#### Tumors

- Squamous cell carcinoma

#### Immunological

- Recurrent aphthous
- Pemphigus
- Lichen planus

#### Miscellaneous

- Lichenoid reaction
- Pyogenic granuloma

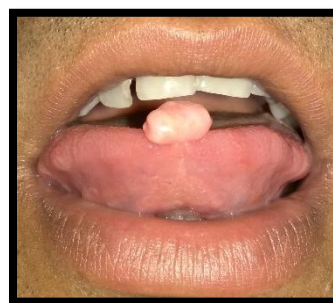Oral fibroma is a common benign scar-like reaction to persistent long-standing irritation in the mouth. It is also known as traumatic fibroma, focal fibrous hyperplasia, fibrous nodule or oral polyp. We report a case of irritation fibroma on the tip of tongue in a 26-year-old male.

#### **Case Report**

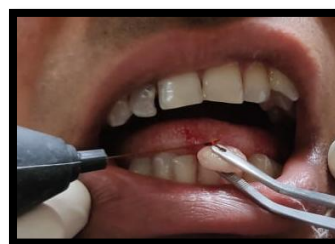A 26-year-old male reported with a small growth of gradual onset on the tip of the tongue since 3-4 years. The growth was round in shape and was measuring approximately 10 mm × 6 mm. It was smooth surfaced, normal mucosal colour and pedunculated. It was firm in consistency and was also non-tender. There was no history of trauma. A clinical diagnosis of fibroma was made and excisional biopsy with laser was planned.

During the surgical procedure tongue was infiltrated by local anesthetic agent followed by excision of growth with diode laser at 1.5 watts and in continuous contact mode. Following the excision of the lesion, patient was advised antibiotics (AXL 500) three times a day and pain killer (Zerodol-P) two times a day for three days. Patient was recalled for evaluation after 1 week and healing was found to be satisfactory.

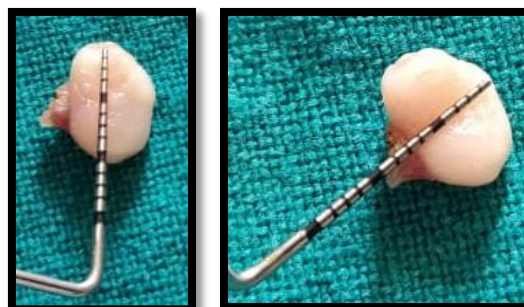Histological examination showed the presence of thin stratified squamous epithelium overlying fibrocellular stroma. The epithelium connective tissue interface was flat. Connective tissue stroma consisted of dense collagen bundles haphazardly arranged along with presence of blood vessels. Based on these findings, a diagnosis of fibroma was given.



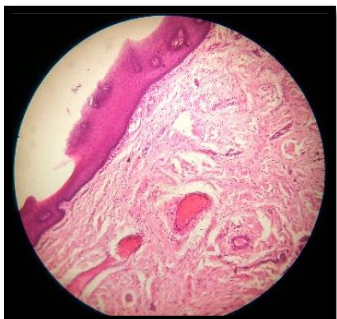
**Fig. Pre-opt**



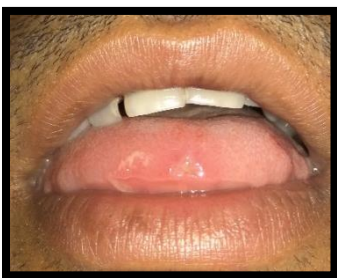**Fig. Excision by laser**



**Fig. Excised growth**



**Fig. Histopathological image**



**Fig. Post-opt**

### **Discussion**

Oral fibroma is most commonly seen in older adults but can occur at any age. It affects 1-2% of adults. It is usually due to chronic irritation such as cheek or lip biting, rubbing from a rough tooth, dentures or other dental prostheses.<sup>1</sup>

Oral fibroma presents as a firm smooth lump in the mouth. It is usually of the same colour as the rest of the lining of oral cavity but is sometimes paler or, if it has bled, may take a dark colour. The surface may be ulcerated due to trauma, or become rough and scaly. It is usually dome-shaped but may be on a short stalk like a polyp (pedunculated). If it has developed under a denture it may be flat with a leaf-like shape.<sup>4</sup>

The commonest location for an oral fibroma is on the inside of the cheek where the upper and lower teeth meet. Other common sites include the sides of the tongue, gums and inside the lower lip.

Apart from the feel and appearance, oral fibromas do not cause any symptoms. Oral fibromas develop over weeks or months to reach a maximum size usually about 1cm in diameter, but can sometimes be larger.

Oral fibroma is usually a solitary lesion. When multiple lesions are seen, associated diagnoses need to be considered including tuberous sclerosis, Cowden syndrome, familial fibromatosis and fibrotic papillary hyperplasia of the palate.<sup>5</sup>

Differential diagnoses of oral fibroma are giant cell fibroma, myofibroma and myofibromatosis and peripheral ossifying fibroma. Giant cell fibroma is characterised by giant cells below the epithelium. Myofibromas and myofibromatosis show myofibroblasts in the stroma. Peripheral ossifying fibroma shows bony trabeculae and foci of calcification.<sup>6</sup>

The diagnosis of oral fibroma is suspected clinically when it presents with the usual history and examination findings. A biopsy may be taken to exclude other conditions or to remove the lesion. Histology will then show typical dense fibrous tissue with relatively few cells. The overlying epithelium may be ulcerated, thinned or thickened.<sup>7</sup>

Treatment is usually surgical excision. It may recur after surgery if the source of irritation continues. It is, therefore, also important to manage the source of the irritation.

In present case, laser was used as it offered the advantages of beingless pain, less need for anesthetics (an advantage for medically compromised

patients), no risk of bacteremia, excellent wound healing, no scar tissue formation, bleeding control (dependent on the wavelength and power settings), usually no need for sutures, use of fewer instruments and materials and no need for autoclaving (economic advantages), ability to remove both hard and soft tissues and lasers can be used in combination with scalpels.<sup>8</sup> However, the laser is a tool and not a panacea. There are some disadvantages of using lasers like relatively high cost of the devices, a need for additional education (especially in basic physics), every wavelength has different properties and the need for implementation of safety measures (i.e. goggles, etc.).<sup>5</sup>

Follow up of 3-4 months was seen and there was no such growth present on the tip of the tongue.

### **Conclusion**

Irritation fibroma clinically resembles as pyogenic granuloma, giant cell fibroma myofibroma or odontogenic tumors, so histopathological examination is essential for accurate diagnosis.

### **References**

1. Bagde H, Waghmare A, Savitha B, Vhanmane P. Irritation fibroma – A case report. *Int J Dent Clinics*. 2013; 5(1):39-40.
2. Anuradha Sunil, Jacob Kurien, Archana Mukunda, Ashik Bin Basheer, Deepthi. Common Superficial Tongue Lesions. *Indian Journal of Clinical Practice*, Vol. 23, No. 9 February 2013: 534-42.
3. Madhusudan AS, Gupta S, Sowmya GV. Focal Fibrous Hyperplasia: Report of two Cases. *Int J Dent Clinics*. 2011;3(1):111-2.
4. Vujhini SK, Reddy SE, Sudheer MVS, Katikaneni HK. Irritation fibroma of tongue:

a case report. *Int J Res Med Sci* 2016; 4:1272-3.

5. Georgios Romanos 1, 2. Current concepts in the use of lasers in periodontal and implant dentistry. *J Indian Soc Periodontol*. 2015 Sep-Oct; 19(5): 490–494.
6. Gonsalves WC, Chi AA, Neville BW. Common oral lesions: Part II. Masses and neoplasia. *Am Fam Physician* 2007; 75: 509-12.
7. Lederman DA, Fornatora ML: Oral fibromas and fibromatoses – Medscape Reference.
8. Stoopler ET, Alawi F. Clinicopathologic challenge: a solitary submucosal mass of the oral cavity. *Int J Dermatol* 2008; 47: 329–331.