

CASE REPORT***Inflammatory fibro-epithelial hyperplasia: a complete overview from diagnosis to treatment***Priyanka Kumari¹, Anubha Nirwal², Shweta Aggarwal², Ankita Mutt¹**Abstract**

Fibroepithelial hyperplasia's are reactive-progressive proliferation of oral mucosa in response to injury or local irritation and gives rise to variety of lesions named according to their clinical presentation. It is a histological variant of fibroma and because of their proliferative nature, they often cause aesthetic and functional problems. The objective of this was to attain complete excision of the growth and send it for histopathological examination to confirm the diagnosis. A 38-year-old male reported to the outpatient Department of Periodontology, Kothiwal Dental college and Research Centre, Moradabad, presented with a chief complaint of gingival overgrowth in the lower right back tooth region for the past 1 year. The growth, which was initially smaller, gradually increased to attain the present size and presented with no history of pain, bleeding, or pus discharge in respect to the site of growth. Identification of any inflammatory hyperplastic gingival lesion requires the formulation of a differential diagnosis to enable accurate patient evaluation and management. A biopsy will ensure a better and a more ideal treatment plan for the patient and prevent recurrence of these lesions

Keywords: Inflammatory fibroepithelial hyperplasia, gingival cyst of adult, periapical cyst

Introduction

Gingival overgrowth, whether generalized or localized, refers to an enlargement of the gingival tissues.

This term has supplanted gingival hyperplasia, which denotes an increase in cell number, and gingival hypertrophy, which signifies an increase in cell size. True enlargement encompasses alterations in cell size, cell multiplication, gingival vasculature, and the extracellular matrix to varying extents.

Following are the various gingival overgrowth conditions like Chronic inflammatory gingival overgrowth, Fibrous epulis, Pyogenic granuloma, Plasma cell gingivitis, certain benign conditions like papilloma, Peripheral giant cell granuloma, Central giant cell granuloma, overgrowths occurring due to hormonal conditions like puberty, pregnancy, menstruation, drug induced gingival overgrowths.^{1,2}

Fibroepithelial hyperplasia (FH) is a lesion categorized under the focal reactive overgrowths and caused mainly by chronic and low-grade irritation of microbial plaque, trauma or any other irritants. Similarity to benign neoplastic proliferations in clinical appearances is troublesome in differential diagnosis. Although etiology and pathogenesis of FH are still not well established, it could be linked to three factors: individual susceptibility, local factors and drugs.³

The histological alterations observed in the mucosal tissues can be classified as hypertrophy, characterized by an increase in the size of cellular elements, or hyperplasia, characterized by an increase in the number of cellular elements.⁴

The oral mucosa is constantly exposed to various external and internal factors, leading to a wide spectrum of diseases, including developmental, reactive, inflammatory, and neoplastic conditions.^{5,6}

Fibroma is the predominant form of oral fibrous proliferation, characterized as a localized increase in fibrous tissue due to trauma or local irritation. This category of lesion occurs in 1.2% of adults and constitutes the leading type of oral mucosal mass undergoing biopsy. Its primary composition includes Types I and III collagen. While gingival lesions are also common, they are more likely to arise from chronic infection rather than traumatic factors.⁵

Irritation fibroma is the most common oral fibrous growth and arises from the gingival connective tissue and periodontal ligament.⁷ Irritation fibroma, or traumatic fibroma, which occurs in response to trauma from teeth or dental prostheses was first reported in 1846 as fibrous polyp and polypus.⁸

1. Post Graduate Student

2. Professor

*Correspondence Address:

Dr. Priyanka Kumari

priyankak511@gmail.comDepartment of Periodontics Kothiwal Dental College
& Research Centre

The lesions are generally asymptomatic and appears as a raised mass (dome shaped nodule) that is pedunculated or sessile with a smooth surface and is usually the same colour as the surrounding gingiva. The nodule is usually less than 1 cm in diameter. If traumatized the surface may ulcerate and alter the pale pink colour of the lesion.⁹

Histologically, fibroblasts scattered in a dense, collagenous matrix, mild chronic, inflammatory infiltrate may be present, but is not a consistent finding.¹⁰ The lesion is managed by surgical excision and has an excellent prognosis with a low recurrence rate.

Case report

A 38-year-old male reported to the outpatient Department of Periodontology, Kothiwal Dental college and Research Centre, Moradabad, presented with a chief complaint of gingival overgrowth in the lower right back tooth region for the past 1 year. The growth, which was initially smaller, gradually increased to attain the present size and presented with no history of pain, bleeding, or pus discharge in respect to the site of growth.

On intraoral examination, a well defined (Figure 1) round shaped sessile fibrous overgrowth, pink in colour, was evident on the lower right posterior tooth region extending superoinferiorly from the marginal attached gingiva overlying mucosa measuring approximately 9mm mesiodistally x 5mm apicocoronally, with smooth and glossy surface texture (Figure 3) which appears to be erythematous and on palpation it is tender on percussion, soft and firm in consistency and is non palpable.

Oral hygiene status of the patient good. Based on the patient's history and clinical findings, a provisional diagnosis of gingival cyst of adult was made in relation to 47 and differential diagnosis of periapical cyst and fibroepithelial hyperplasia was made.

Case management

The patient was subjected to routine haematological and radiographic investigations. Blood investigation was within normal limits. Intraoral peri-apical radiograph revealed no widening of periodontal ligament space with no crestal bone loss and no evidence of periapical pathology (Figure 4).

Following phase I therapy of in which complete supra and sub-gingival scaling and proper oral hygiene instructions were given. A week after SRP (Figure 2), excisional biopsy was performed in relation to 47(Figure 6). Before excision, the lesion was measured apicocoronally and mesiodistally as 9 x 5 mm, respectively (Figure 3). After adequate local anaesthesia, complete excision including 2 mm of healthy tissue was done using scalpel (Figure 5). Complete curettage was done, and periodontal dressing was placed (Figure 6,7).

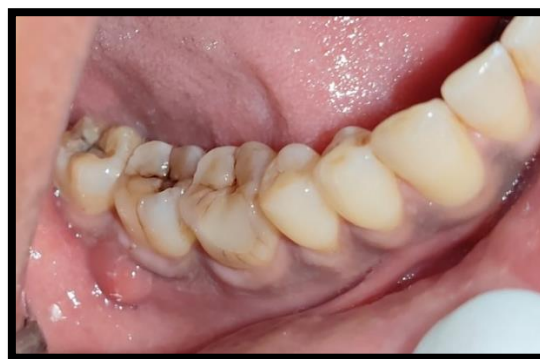

Figure 1 - Baseline picture

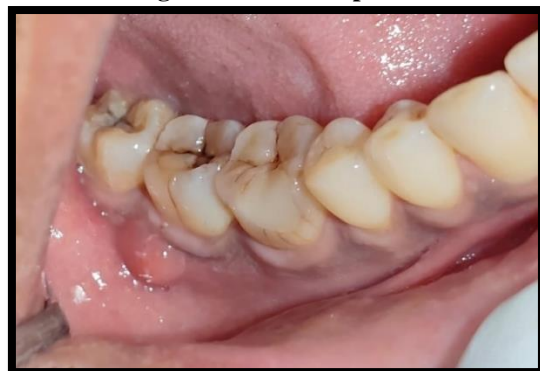

Figure 2 - 61 week after scaling and root planing

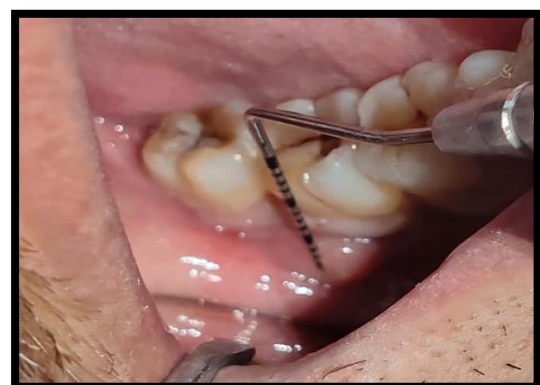
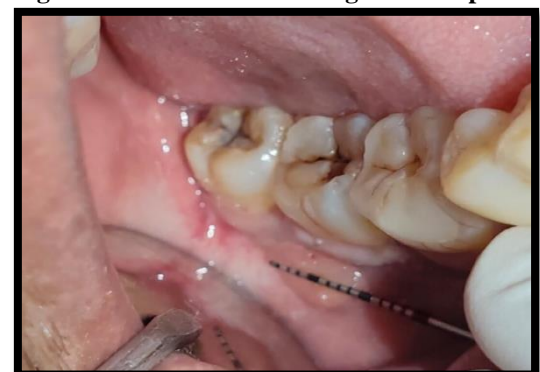
Figure 3(a,b) - Baseline measurements 9mm mesiodistally x 5mm apicocoronally



Figure 4 - Pre -op IOPA

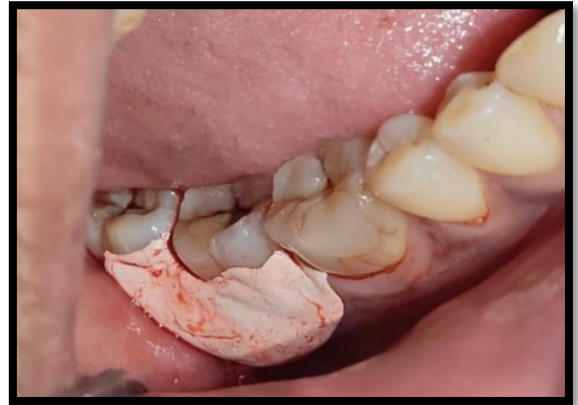

Figure 7 - Periodontal dressing placed

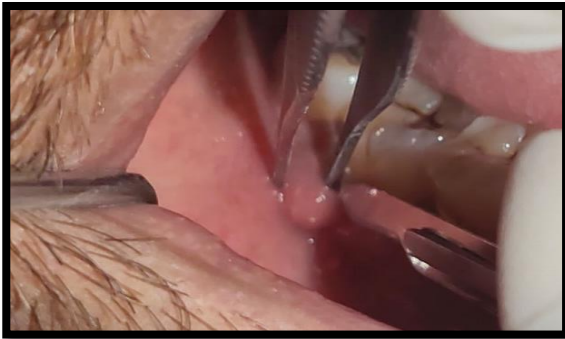

Figure 5 - Complete excision of the lesion using

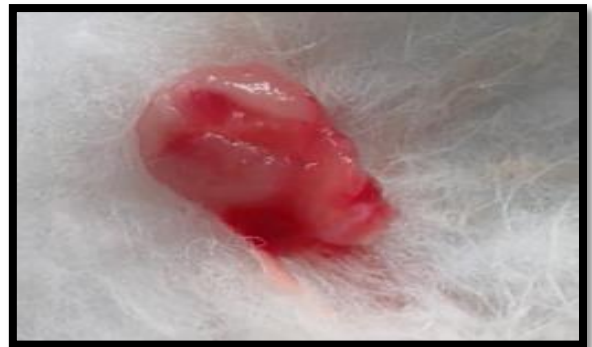

Figure 8 - Excised tissue

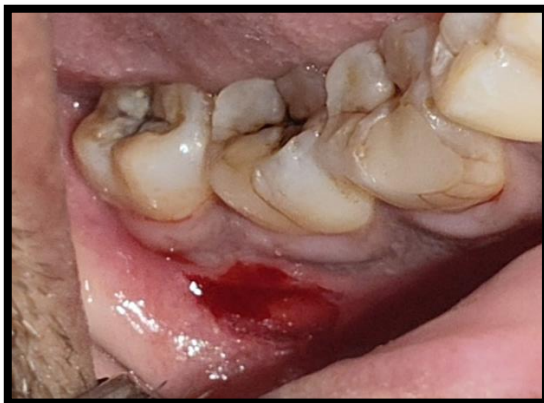

Figure 6- Complete curettage done

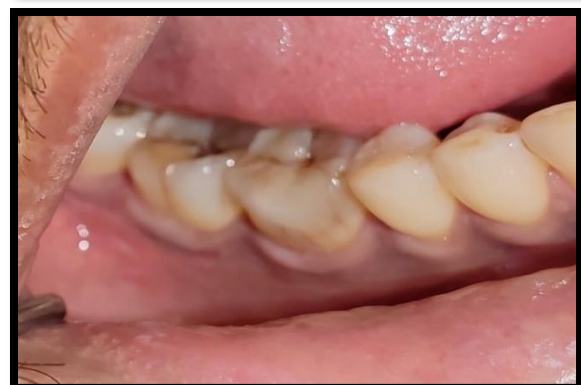
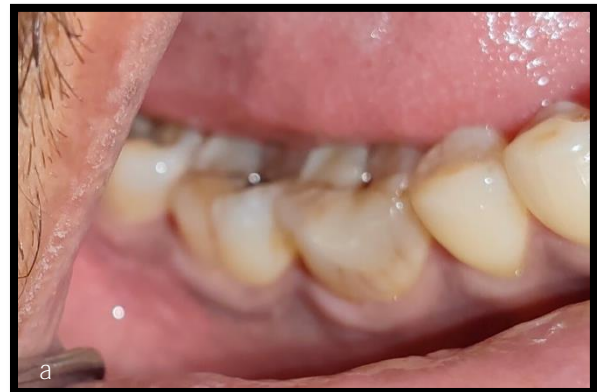
Figure 9 - Post op picture - (a)2 weeks (b)1month

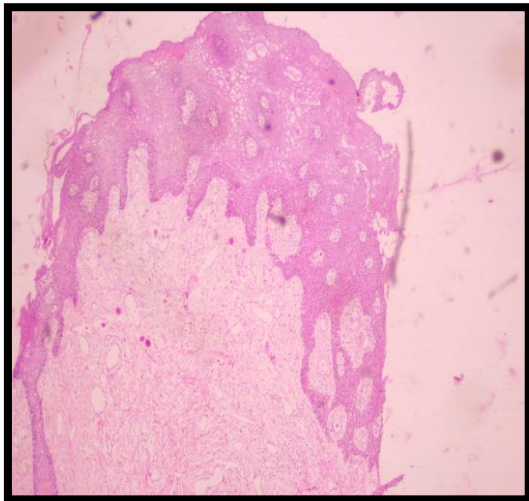


Figure 10 - Histopathological picture of Fibroepithelial hyperplasia. (4x)

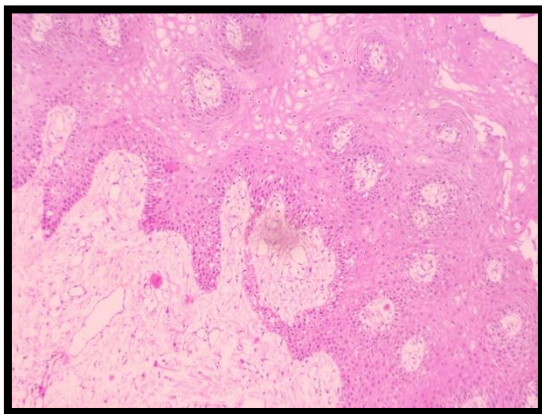


Figure 11 - Histopathological picture of Fibroepithelial hyperplasia

Post surgical care and follow up

Post operative instructions were given, and medications prescribed. Analgesics (Zerodol SP) and antibiotics (Amox CV 625 mg) thrice daily for three days was advised to the patient. 0.12% chlorohexidine mouthwash twice daily was prescribed for the first 15 days. The periodontal dressing was removed 14 days after excision (Figure 9).

Clinical outcomes

14 days after the excision, there was 100% healing, with increase no visible sign of inflammation and gingiva at the site was apparently healthy. No scar formation was observed and the color match of the tissue was excellent with no gingival recession observed irt 47 (Figure 9).

Histopathological investigations:

Hematoxylin and Eosin stained soft tissue section shows parakaratinized hyperplastic stratified squamous epithelium overlying a fibro-cellular connective tissue stroma. The epithelium shows long and branched rete ridges with entrapped connective tissue stroma. The connective tissue stroma shows densely arranged collagen fibres in association with fibroblast, numerous endothelial lined

blood vessels filled with RBCs and densely packed infiltration of chronic inflammatory cells predominantly consisting of lymphocytes and plasma cells (Figure 10, 11). So, confirmed histopathological diagnosis of

Discussion

Almost all lesions in the oral cavity that are called fibromas are not true neoplasms.¹¹ Fibrous inflammatory hyperplasia may occur on any surface of the oral mucous membrane as either pedunculated or sessile growth. Lesions more than one cm in diameter are rare in cheeks, tongue and floor of the mouth because masticatory stresses restricts their size through necrosis and ulceration.¹² In this patient, the involved gingiva appeared to be firm without spontaneous bleeding and the presence of plaque and calculus could be the cause for the proliferation of gingival tissue and the chronicity of irritation would have resulted in the fibrotic nature of the gingiva.

Fibro epithelial hyperplasia's when inflamed are covered by uniformly hyperplastic epithelium, with arcading rete pattern when ulcerated. Thin spiky or elongated bilaminar rete processes are seen which penetrates deeply into the connective tissue. This rete hyperplasia is prominent when marked inflammation is present, but in less inflamed lesions epithelium becomes regular with flat basement membrane or may get atrophied.¹³

Inflammatory fibrous hyperplasia or fibrous hyperplasia is a benign soft tissue response to a local irritant. It can be due to calculus, a sharp tooth, a broken filling, excessive plaque and other irritat- ing factors. Fibrous hyperplasia clinically presents as a well-demarcated exophytic mass. The color ranges from normal to white or reddish depending upon whether or not the surface is ulcerated, keratotic or both or neither. It can be soft or firm in palpation.¹⁴

Histologically, inflammatory fibrous hyperplasia is made up of a mass of hyperplastic connective tissue with dilated blood vessels, usually with chronic inflammatory cells such as lymphocytes and plasma cells, but it can also be made up of solid connective tissue with minimum to no inflammatory cells, the latter called fibrous hyperplasia. The surface epithelium ranges from normal to acanthotic, ulcerated, keratotic or a combination of two or more of these features.¹⁵

Surgical excision is the preferred treatment of choice, with removal of local irritants to prevent recurrence. For hyperplastic lesions, a conservative approach is recommended. Local irritants should be removed. Those lesions failing to resolve should be surgically excised. Follow-up of the patient is needed as it exhibits a tendency to recur.¹⁶

Conclusion:

Identification of any inflammatory hyperplastic gingival lesion requires the formulation of a differential diagnosis to enable accurate patient evaluation and management. A biopsy will ensure a better and a more ideal treatment plan

for the patient and prevent recurrence of these lesions These hyperplastic conditions are considered self-limiting. But since they interfere with form and function, they need to be excised. Also, longstanding hyperplastic lesions in the presence of chronic irritation can get converted to neoplasia.

References

1. Dhingra K, Prakash S. gingival overgrowth in partially edentulous ridges in an elderly female patient with epilepsy: a case report. *gerodontology*. 2012;29(2):e1201-6 10.1111/j.1741-2358.2012.00624.x. pmid: 22612838.
2. Carty O, Walsh E, Abdelsalem A, Macarthy D. case report: drug-induced gingival overgrowth associated with the use of a calcium channel blocker (amlodipine). *J IR Dent Assoc*. 2015;61(5):248-51. pmid: 26665904.
3. Inflammatory fibroepithelial hyperplasia and application of free gingival graft: a case report F. Ong € oz Dede, € S. Celen, K. Gunayd € in Ordu/Turkey
4. Sánchez-torres A, Mota I, Alberdi-Navarro J, CercadilloIbarguren I, Figueiredo R, Valmaseda-Castellón E. Inflammatory fibro-epithelial hyperplasia related to a fixed implant-supported prosthesis: a case report. *J*
5. Suryaprassanna J, et al. fibroepithelial hyperplasia: rare,self-limiting condition – two case reports. *Journal of Advanced Oral Research*. 2011;2(3):63-69.
6. Bello IO, Qannam A. Gingival and alveolar ridge overgrowths: a histopathological evaluation from Saudi Arabia. *Saudi Dent J*. 2022;34(6):509-515. 10.1016/j.sdentj.2022.05.005. epub 2022 may 23. pmid: 36092522; pmcid: pmc9453526
7. Newman MG, Takei H, Klokkevold Pr cf. Carranza's clinical periodontology. 2012.
8. Eversole Ir, rovin s. Reactive lesions of the gingiva. *J Oral Pathol Med*. 1972;1(1):30- 38.
9. Rose L, Mealey B, Genco R CD. *Periodontics: Medicine, Surgery, and Implants* By Louis F. Rose, Brian L. Mealey, Robert J. Genco, and D. Walter Cohen Elsevier Mosby; Philadelphia: 2004. 990 Pp. Vol 99.; 2004.
10. Prasanna J, Sehrawat S. Fibroepithelial hyperplasia: Rare, selflimiting conditionTwo case reports. *J Adv Oral Res*.
11. Burkitts -Oral medicine for the dental practitioner. 7. Inflammatory overgrowths and neoplasms. *Br Dent J* 1974; 136:111-16.
12. Daley TD, Wysocki GP, Wysocki PD, Wysocki DM. The major epulides: clinicopathological correlations. *J Can Dent Assoc* 1990;56(7):627-30.
13. Shafer, Hine, Levy. Benign and malignant tumours of oral cavity. In:Rajendran, Shivapathasundaram(ed)Shafer's Textbook of Oral Pathology. 5ed. New Delhi, Elsevier.2007:178-180.
14. Zain RB, Fei YJ. Fibrous lesions of the gingiva: A histologic analysis of 204 cases. *Oral Surg Oral Med Oral Pathol*. 1990;70:466–70. [PubMed: 2120653]

15. Greenberg MS, Glick M. *Burket's oral medicine: Diagnosis and treatment*. 10th ed. Hamilton, Ontario: BC Denker; 2003. pp. 138–9.
16. Rose LF, Mealey BL, Genco RJ, Cohen DW. *Periodontics: Medicine, surgery, and implants*. 2nd rev ed. St Louis, Missouri: Elsevier Mosby; 2004. p. 882.